

## Ceramic laminate Veneers: A Minimally Invasive Approach for Tooth Esthetic Restoration

Ashwag Ali Showail<sup>1</sup> and Ahmed Mohamed Elmarakby<sup>2,3\*</sup>

<sup>1</sup>Dental intern at Alfarabi colleges for Dentistry & Nursing, Riyadh, Saudi Arabia.

<sup>2</sup>Assistant Professor at Restorative Dentistry, Al-Farabi Colleges for Dentistry & Nursing Riyadh, Saudi Arabia.

<sup>3</sup>Lecturer of Operative Dentistry, Faculty of Dentistry, Al-Azhar University, Egypt.

### \*Correspondence:

Ahmed Mohamed Elmarakby, Assistant Professor at Restorative Dentistry, Al-Farabi Colleges for Dentistry & Nursing and Lecturer of Operative Dentistry, Faculty of Dentistry, Al-Azhar University, Assiut Branch, Egypt, Tel: 00966506676440; E-mail: drahmedmarakby@yahoo.com.

Received: 20 September 2017; Accepted: 04 October 2017

**Citation:** Ashwag Ali Showail, Ahmed Mohamed Elmarakby. Ceramic laminate Veneers: A Minimally Invasive Approach for Tooth Esthetic Restoration. Int J Oral Health Dent Manag. 2017; 1(1); 1-5.

### ABSTRACT

*As esthetic dentistry may be represented a modified form of restorative dentistry. Correction of minor malformations of anterior teeth with minimal removal of the remaining tooth structure, correction of crown length and width, diastma closure and masking some intrinsic discoloration of anterior teeth like dental fluorosis and tetracycline staining are examples for solutions that can be gained with using ceramic laminate veneers. Correct placement, proper application and appropriate selection of ceramic veneer material is the aim of this current literature which focusing on the most important parameters that may be responsible for the long term success of minimally invasive veneers.*

### Keywords

Minimal invasive dentistry, Ceramic laminate veneers, Tooth minor corrections.

### Introduction

Ceramic veneers with minimal or sometimes with no tooth reduction may establish better esthetics and in some cases considered the more conservative esthetic restoration. Teeth with mal-alignment, traumatic teeth, discolored teeth that have a poor response to bleaching, large tooth fracture that is not easy to restore with direct composite restoration and severely anterior teeth wear are some indications for ceramic veneers [1].

One of the best collections of indications and classification for veneers are that done by Magne and Belser. They classified the indications into three main types I, II and III then every main type was further subdivided into A, B and C. Type I refer to indications of veneers in teeth that are resisting bleaching procedures. This type divided into Type IA; that refers to tetracycline discoloration which is considered the most resistance type for teeth bleaching especially the Grayish blue tetracycline type. Type IB; that refers to any other types of teeth discoloration that is unresponsive to the

teeth bleaching procedures. Type II refer to indications of veneers in teeth with Major morphologic modifications. This type divided into Type IIA; that refers to teeth with conical appearance e.g. Pig shaped lateral. Type IIB; that refers to teeth need for closure of diastema or closure of interdental spacing. Type IIC; that refers to teeth need for incisal length augmentation. Type III refer to indications of veneers in teeth with extensive large restorations. This type divided into Type IIIA; that refers to teeth with Extensive fracture of coronal portion. Type IIIB; that refers to teeth with Extensive enamel loss due to wear and erosion. Type IIIC; that refers to teeth suffering from generalized congenital malformations [2]. It appears that regarding this sophisticated classification, Type I and Type II can be restored their esthetic appearance through Ceramic veneers with minimal or no-preparation technique.

The first use for ceramic veneers was by manners, techniques and fabricated materials that were different from current state. Thickness available at this time was 0.5-0.7 mm and stacked feldspathic porcelain was the material of fabrication. Regarding the technique of tooth preparation, there was a trend of establishment of No-Preparation manner [3]. Drawbacks that has been observed were bulky appearance veneer due to up to 0.7 mm thickness

that cemented to non-prepared teeth, lack of retention due to absence of finishing line and some degree of cement dissolution and observation of signs of soft tissue irritation due to trapping of remaining food debris around the margins of veneers.

All efforts were exerted by the recent dental laboratories and manufacturers to meet the demands of patient and dentist. The less thickness veneers with minimum or no preparation techniques become a real. The new era of veneer materials and cements were achieved all the requirements of veneer desired position, proper veneer shape and shade in addition to the advantage of tooth structure conservation by minimal reduction without previous drawbacks of bulky appearance veneer, lack of retention and observation of signs of soft tissue irritation due to trapping of remaining food debris around the margins of veneers. The “No-Preparation” technique may be more acceptable to apply with patient with lingually drifted teeth. In general, there are many advantages of Minimal or no-prep technique including reduce the post-operative pain, less need for anesthesia, better retention due to bond to enamel, reduce flexural stresses and restoration is lasting for long term [4,5]. The continuity of more developed materials and techniques lead to the Porcelain laminate veneers which represented the approach of conservative and minimal invasion of tooth structure that is provide highly rigid, polishable and biologically tolerable restoratives. The stained, discolored unesthetic areas of tooth structure can be masked by a thin shell of porcelain laminate veneers with a thickness less than 0.5 mm that is provide the lower limit of strength enough for lab fabrication and delivery [6-8]. Nowadays, some expressions like Hollywood smile and Luminaires are widely used among patients, labs and dentists. The more scientific accepted name is porcelain laminate veneers continue the cycle of improvement in the field of restorative and esthetic dentistry that can provide healthy, biologically compatible and more esthetically accepted restoration. This literature review discusses the minimal invasive preparation of tooth structure and the recent techniques and materials used in porcelain laminate veneers as a revolutionary solution for esthetic and restorative dentistry.

### Preparation of incisal edge

Three preparation designs have been suggested regarding the incisal edge preparation of ceramic laminate veneers as seen in figure 1. The window or inter-enamel preparation, the incisal bevel 0.5-1 mm and the edge-lapped or the overlapped incisal edge 2-4 mm preparation. For the first technique of preparation; the window or inter-enamel preparation is commonly used for minimal teeth preparation that suffering from stains or discoloration with no need for crown length correction. In this technique, the main preparation is on the labial or facial tooth surface and the incisal portion just prepared from facial surface and no preparation at all done at both incisal edge and palatal surface. The disadvantages confined to ill retention and somewhat weakening incisal portion of ceramic laminate veneers. For the second technique of preparation; Castelnuovo et al. revealed that the incisal bevel 0.5-1 mm that resulted in nearly a butt joints and the reduction of palatal area of incisal edge to make a chamfer finishing line will

lead to more strength of veneer at this area in addition to easy preparation technique [9]. They also concluded that to decrease the risk of broken thin shell non-supported ceramic laminate veneers ledges especially in case of multiple veneers, the path of insertion in facial palatal direction that resulted from that type of technique will strongly achieving that purpose in addition to easy adapted and well fitted surfaces in the case of multiple numbers of ceramic laminate veneers.

Regarding the third preparation technique i.e. the edge-lapped or the overlapped incisal edge 2-4 mm preparation; the study of Akoğlu and Gemalmaz [10], have been assessed the failure mode and the load of fracture of ceramic laminate veneers when the preparation are done and finished at either enamel or dentin. They revealed that the lower fracture load was achieved when 4 mm incisal reduction entirely done on dentin surface than those of only 2 mm dentin reduction at incisal edge. They also concluded that the fracture resistance was nearly similar with no statistical significant difference for both veneers that the preparation of teeth was less than 2 mm in dentin of the incisal edge area and the intact teeth with no preparation at incisal edge (the window type). It is more acceptable for patients that need more strength long lasting veneers that dentist should choose the technique of incisal edge preparation either by beveling (0.5-1 mm) or by complete overlapped technique (2-4 mm). In this case, it is preferable when preparing the palatal tooth surface and incisal edge reduction to use the silicone index than depth gauge bur that will be not useful in this situation [11].

### Preparation of labial surface

Because this surface resembles the most esthetic portion of ceramic laminate veneers, obtaining the accurate preparation depth can be achieved via several methods. Use of depth cutter burs figure 2 to make slanted grooves or cuts that control preparation depth are very useful. The recommended depth for minimal invasive approach is 0.5 mm. The silicon putty index after wax up may be also helpful but less than its usefulness in the area of incisal edge preparation. Some expertise highly experienced and well trained operators using a “free-hand” technique with no depth preparation guidance depending on their tactile sensation. Free-hand technique is not recommended for beginners and newly dentist to avoid the risk of overcutting or unequal reduction levels of labial tooth surface. Nattress et al. revealed that dentin exposure and variable preparation depth can be resulted from using free-hand technique [12].

In the study of Ferrari et al. [13] they evaluated and measured the labial surface of one hundred fourteen extracted human teeth at three locations, the incisal, the middle and the gingival thirds. Examined teeth were variables of anterior teeth and premolars and they tried to measure the labial enamel thickness at these sites. They revealed that there is a problem should be solved that was the enamel of labial surface should be reduced 0.5 in all mentioned thirds in order to get a proper thickness for ceramic laminate veneer at labial surface that is enough to mask any minor tooth stains or discoloration. But they found that thickness of enamel

differed in the three third, while thickness was 1-1.5 mm at incisal third, 0.5-0.7 mm at Middle third, It was 0.3–0.4 mm at gingival third. This would lead to either removal of all enamel thickness in addition to dentin exposure during proper gingival third reduction or if operator adopts minimal invasive approach he had to less reduction at this area but an over-contoured veneer could be the final result. The dilemma was that the more conservative less reduction at gingival third will lead to bulky veneers with subsequent gingival problems as the normal labs and technicians unable to reduce the veneer thickness at this area. On the other hand, the more extensive exposure of dentin would result from over-reduction [14-16].

In the study of Ferrari et al. [13] they evaluated and measured the labial surface of one hundred fourteen extracted human teeth at three locations, the incisal, the middle and the gingival thirds. Examined teeth were variables of anterior teeth and premolars and authors tried to measure the labial enamel thickness at these sites. They revealed that there is a problem should be solved that was the enamel of labial surface should be reduced 0.5 in all mentioned thirds in order to get a proper thickness for ceramic laminate veneer at labial surface that is enough to mask any minor tooth stains or discoloration. But they found that thickness of enamel differed in the three third, while thickness was 1-1.5 mm at incisal third, 0.5-0.7 mm at Middle third, It was 0.3–0.4 mm at gingival third. This would lead to either removal of all enamel thickness in addition to dentin exposure during proper gingival third reduction or if operator adopts minimal invasive approach he had to perform a less reduction at this area but an over-contoured veneer could be the final result. The dilemma was that the more conservative less reduction at gingival third will lead to bulky veneers with subsequent gingival problems as the normal labs and technicians unable to reduce the veneer thickness at this area. On the other hand, the more extensive exposure of dentin would result from harmful over-reduction [14-16]. As mentioned before, the risks with free-hand technique include appearance of areas of both unnecessarily extensive reduction and inadequate under-preparation within the same tooth surface. Using of depth gauge bur or silicon putty index silicon is highly recommended for newly dentists when teeth to be prepared for ceramic laminate veneers. Only in case of severely intrinsic teeth discoloration like deep grayish blue tetracycline stains figure [4], using of a non-uniform preparation e.g. free-hand technique may be preferable to prevent stain display under the thin ceramic veneers in order to increase the esthetic outcome success. The shade and quality of used resin cement and the thick bulky veneer increasing the ability of stain masking [17]. Nowadays, the introduction of newly ceramics fabrication devices, and increase the numbers of highly skilled, well trained ceramic technicians, increasing the ability to adopt the minimally invasive approach of tooth preparation for porcelain laminate veneers.

Some authors [7] revealed that the no-preparation technique before veneer placement can be strongly recommended in some situations without interfering with gingival tissue health. Tooth with lingual retraction between another normal tooth is more prominent example for this recommendation. Thickness of veneer is in the

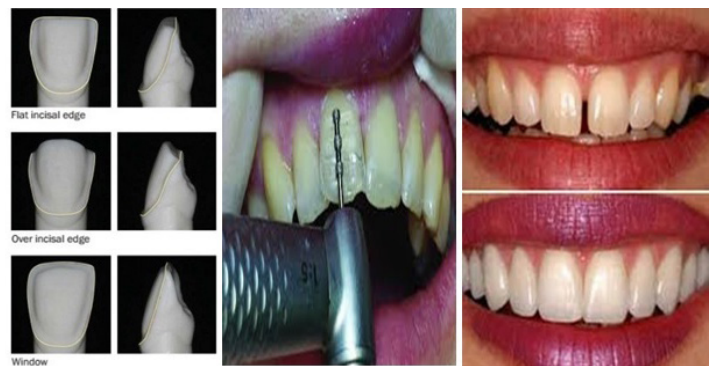
opposite of tooth reduction. Fabrication of small thickness veneers means that operator followed the approach of minimally invasive tooth preparation. This can be recommended in case of less teeth stains or non-sever intrinsic discoloration that can be easily esthetically improved by minor teeth preparation and masked by smaller thickness veneers [2,11,18].

In general, during preparation of porcelain laminate veneers, it is recommended to use the minimally invasive technique with teeth need for minimal correction at the incisal edge, in diastma closure, figure 3 in modifications of small fractures at incisal angle of anterior teeth and when indirectly restored the pig-shaped lateral incisors. Preservation of incisal edge intact without preparation may lead to just facial window type of preparation and no need for incisal edge-overlapped type. Although edge-lapped preparation type gives more retention and resistance for porcelain laminate veneers, it is not recommended if there is no need for correction of tooth crown length.

Nowadays, with more recent devices and well trained highly skilled dentist and ceramic technicians, the cervical third reduction with minimally invasive approach for porcelain laminate veneers became (0.1 mm), the middle third reduction became (0.2-0.5 mm) and the incisal edge reduction became (0.7-1.0 mm) [18].

### Preparation of interproximal surface

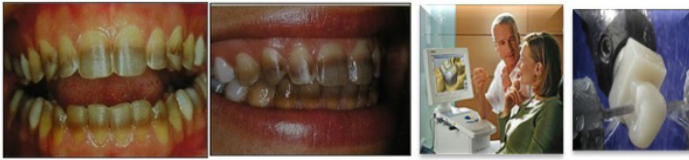There is no restricted role regarding the interproximal tooth preparation for ceramic veneers. Some authors recommended no-preparation especially with window type technique that is indicated when there is a minor tooth discoloration confined to facial surface with no interproximal extensions. Another authors group suggested conservative preparation that stops before opening the interproximal contacts. This may be recommended if the discoloration in the previous situation extended to proximal area. In case of diastma closure using porcelain laminate veneers, slight opening of teeth interproximal contacts was recommended with researchers. In some situation when preparing a multiple teeth with tight contact, a “slice preparation” or breakage of the contact may be advisable in order to free-way the contacts for two reasons; position or shape correction and enhance better performance of the technician in contour adjustment [19,20].



**Figure 1:** Types of facial prep.

**Figure 2:** Depth cutter burs.

**Figure 3:** Diastma closure by veneer.



**Figure 4:** Heavy tetra-cyclin stained teeth.

**Figure 5:** CAD/CAM system.

### Cervical margin preparation

Cervical margins of porcelain laminate veneers is one of the critical areas from esthetic and biological points of view. Finishing line may be at one of three locations; supra-gingival, at gingival or sub-gingival.

Supra-gingival finishing line is more hygienic and biological for gingival tissues but less esthetic. Chamfer finish line is more accepted and will be more beneficiary for ceramics technician to determine where to build and construct the porcelain laminate veneers [2,21]. Sub-gingival finishing line is more esthetic but less biocompatible for gingival tissues. This type can be used efficiently in case of severely discolored teeth like in case of tetracycline stains to mask the undesirable discoloration at cervical margins. Cervical region are area of challenge for luting cement as fluids secreted from gingival crevice impair a good seal between the fitting surface of laminate veneer and the tooth structure. Most studies concluded that if the tooth preparation was more conservative and confined to enamel, the bond strength between recent resin cements and enamel will be better than with dentin [6,22,23].

### Materials used for laminate veneers

There are three types of materials may be used for ceramic laminate veneers; porcelain fired on refractory dies, hot pressed glass ceramic and chair-side computer aided design\computer assessed manufacturing (CAD-CAM) system.

The material of porcelain fired on refractory dies is feldspathic porcelain in which Porcelain restorations are made from finely ground ceramic powders that are mixed with distilled water or a special liquid. Regarding the technique of fabrication: After tooth preparation, an impression is made, and a “master” working cast is poured of die stone. The die is duplicated and poured with a refractory investment capable of withstanding porcelain-firing temperatures. Porcelain is added into the preparation area of the refractory die and fired in an oven. The ceramic laminate veneer is recovered from the refractory die, cleaned of all investment, seated on the master die and working cast for final adjustments and finishing. Advantages of this type are: Low startup cost, the ceramic powders and investments are relatively inexpensive and the technique is compatible with most existing ceramic laboratory equipment. The Disadvantage of this type may be its technique sensitivity and many dentists complain of problems with fit and strength. In addition porcelain laminate veneers fabricated with this technique must be handled gently during try-in to avoid fracture and even after cementation; the incidence of fracture is

high for this type of ceramic laminate veneers [24-26].

Regarding the second type; the hot pressed glass ceramic, in 1968, it was discovered that certain glasses could be modified with nucleating agents and, on heat treatment, be changed into ceramics with organized crystalline forms. Such glass-ceramics were stronger than non-crystalline glass, had a higher melting point than non-crystalline glass and had variable coefficients of thermal expansion. In 1984, the glass-ceramic material Dicor (Dentsply International, York, Penn) was patented and rapidly became a popular ceramic for dental restorations. Dicor restorations were made using a lost-wax, centrifugal casting process. A major disadvantage of Dicor was its translucency, which necessitated external application of all shading. Newer leucite-reinforced glass-ceramic systems also use the lost-wax method, but the material is heated to a high temperature and pneumatically pressed, rather than centrifuged into a mold. Advantages of this type may be its similarity to traditional “wax-up” processes, excellent marginal fit. Also it has a relatively high strength and the surface hardness and occlusal wear of these ceramics are similar to those of enamel. The most important observation is that the incidence of post cementation fracture for pressed ceramic veneer is expected to be lower than that for ceramic veneer fired on refractory dies, but higher than for veneer made with CAD/CAM systems [27-29].

Regarding the last type: chair-side computer aided design \ computer assessed manufacturing (CAD-CAM) system figure 5, it is a computerized device that can fabricate ceramic veneers, inlays and onlays from high-quality ceramics in a matter of minutes eg. Ceric system. The Ceric system was the first commercially available CAD/CAM system developed for the rapid chair-side design and fabrication of ceramic restorations. Steps of fabrication include an Optical impression that is taken after tooth preparation. Dentist uses a scanning device (intra-oral camera) to collect information about the shape of the preparation and its relationship with the surrounding structures. Cerec systems use the optical techniques of Moire fringe displacement and active triangulation to measure the height and depth of the preparation. The system projects an image of the preparation and surrounding structures on a monitor, allowing the dentist or auxiliary personnel to use the CAD portion of the system to design the restoration. The operator must input or confirm some of the boundaries of the restoration, such as the position of the gingival margins. The Steps of fabrication include the use of the micro-milling machine (CAM portion of the system). A micro-milling devise mills the restoration out of a block of high-quality ceramic or composite in minutes. The restoration is removed from the milling device, ready for try-in, contouring, cementation, and polishing. The Advantages may be that the CEREC systems are designed to be used chair-side and in the laboratory. Also the chair-side use eliminates the need for a conventional impression, temporary restoration, and multiple appointments. The major advantage is the high quality of the final restorative material. Manufacturers make blocks of “machinable ceramics” or “machinable composites” specifically for computer-assisted milling devices. On the other hand, disadvantages may be confined in technique high coast and need for extra training [30-32].

## Conclusions

The keys of success of ceramic laminate veneers may be depending to the large extent on well trained, good experienced dentist and ceramic technician. Increasing knowledge of types and techniques of laminate veneer preparation for dentists and raising the awareness of types of veneer materials, techniques of fabrication and newly devices for lab technicians are very important step to gain excellent final results that will be very satisfied for pt. demands.

## References

1. Peumans M, Van Meerbeek B, Lambrechts P, et al. Porcelain veneers: a review of the literature. *J Dent.* 2000; 28: 163-177.
2. Magne P, Belser UC. *Bonded Porcelain Restorations in the Anterior Dentition-a Biomimetic Approach.* Chicago: Quintessence Publishing Co. 2002.
3. Calamia JR, Calamia CS. Porcelain laminate veneers: reasons for 25 years of success. *Dent Clin North Am.* 2007; 51: 399-417.
4. Malcmacher L. No-preparation porcelain veneers – back to the future! *Dent Today.* 2005; 24: 90-91.
5. Javaheri D. Considerations for planning esthetic treatment with veneers involving no or minimal preparation. *J Am Dent Assoc.* 2007; 138: 331-337.
6. Radz GM. Minimum thickness anterior porcelain restorations. *Dent Clin North Am.* 2011; 55: 353-370.
7. Wells DJ. “No-prep” veneers. *Inside Dent.* 2010; 6: 56-60.
8. Edelhoff D, Sorensen JA. Tooth structure removal associated with various preparation designs for anterior teeth. *J Prosthet Dent.* 2002; 87: 503-509.
9. Castelnuovo J, Tjan AHL, Phillips K, et al. Fracture load and mode of failure of ceramic veneers with different preparations. *J Prosthet Dent.* 2000; 83: 171-180.
10. Akoğlu B, Gemalmaz D. Fracture resistance of ceramic veneers with different preparation designs. *J Prosthodont.* 2011; 20: 380-384.
11. Brunton PA, Aminian A, Wilson NH. Tooth preparation techniques for porcelain laminate veneers. *Br Dent J.* 2000; 189: 260-262.
12. Nattress BR, Youngson CC, Patterson CJ, et al. An in vitro assessment of tooth preparation for porcelain veneer restorations. *J Dent.* 1995; 23: 165-170.
13. Ferrari M, Patroni S, Balleri P. Measurement of enamel thickness in relation to reduction for etched laminate veneers. *Int J Periodontics Restorative Dent.* 1992; 12: 407-413.
14. Parmeijer CH. Porcelain laminate veneers. *J Calif Dent Assoc.* 1991; 19: 59-62.
15. Weinberg LA. Tooth preparation for porcelain laminates. *N Y State Dent J.* 1989; 55: 25-28.
16. Clyde JS, Gilmour A. Porcelain veneers: a preliminary review. *Br Dent J.* 1988; 164: 9-14.
17. Chen JH, Shi CX, Wang M, et al. Clinical evaluation of 546 tetracycline-stained teeth treated with porcelain laminate veneers. *J Dent.* 2005; 33: 3-8.
18. Pini NP, Aguiar FH, Lima DA, et al. Advances in dental veneers: materials, applications, and techniques. *Clin Cosmet Investig Dent.* 2012; 4: 9-16.
19. Strassler HE, Weiner S. Seven to ten-year clinical evaluation of porcelain laminate veneers. *J Dent Res.* 1995; 74: 176.
20. Walls AWG. The use of adhesively retained all-porcelain veneers during the management of fractured and worn anterior teeth: Part 2. Clinical results after 5 years of follow-up. *Br Dent J.* 1995; 178: 337-340.
21. Dumfahrt H. Porcelain laminate veneers. A retrospective evaluation after 1 to 10 years of service: Part I – Clinical procedure. *Int J Prosthodont.* 1999; 12: 505-513.
22. Aristidis GA, Dimitra B. Five-year clinical performance of porcelain laminate veneers. *Quintessence Int.* 2002; 33: 185-189.
23. Peumans M, De Munck J, Fieuws S, et al. A prospective ten-year clinical trial of porcelain veneers. *J Adhes Dent.* 2004; 6: 65-76.
24. McLaren EA, LeSage B. Feldspathic veneers: what are their indications? *Compend Contin Educ Dent.* 2011; 32: 44-49.
25. McLaren EA, Whiteman YY. Ceramics: rationale for material selection. *Compend Contin Educ Dent.* 2010; 31: 666-668.
26. Calamia JR, Calamia CS. Porcelain laminate veneers: reasons for 25 years of success. *Dent Clin N Am.* 2007; 51: 399-417.
27. K.A. Malament, S.S. Socransky. Survival of Dicor glass-ceramic dental restorations over 16 years. Part III: effect of luting agent and tooth or tooth-substitute core structure. *The Journal of Prosthetic Dentistry.* 2001; 86: 511-519.
28. E.A. Tsitrou, M. Helvatjoglu-Antoniades, R.van Noort. A preliminary evaluation of the structural integrity and fracture mode of minimally prepared resin bonded CAD/CAM crowns, *J Dent.* 2010; 38: I. Denry. "How and when does fabrication damage adversely affect the clinical performance of ceramic restorations?" *Dental Materials.* 2013; 29: 85-96.
29. Berg NG, Derand T. A 5-year evaluation of ceramic inlays (CEREC). *Swed Dent J.* 1997; 21: 121-127.
30. Mörmann WH. The evaluation of the CEREC system. *J Am Dent Assoc.* 2006; 137: 7-13.
31. Duret F, Blonin J, Duret B. CAD/CAM in dentistry, *JADA.* 1998; 117: 715-720.
32. Trifković B, Todorović A, Lazić V, et al. Accuracy of optical scanning methods of the Cerec®3D system in the process of making ceramic inlays *Vojnosanit pregl.* 2010; 67: 795-876.