

Fracture Penis: A Case Report

Vinoth kumar R¹ and Thamilselvam P²

¹Department of Urology, Government Kilpauk Medical College & Hospital, Chennai, India.

²Department of Surgery, Faculty of Medicine and Defence Health, National Defence University of Malaysia, Kuala Lumpur, Malaysia.

***Correspondance:**

Vinoth kumar R, Department of Urology, Government Kilpauk Medical College & Hospital, Chennai, India, Tel: +919944116988; E-mail: urovinoth@gmail.com

Received: 19 Apr 2017; **Accepted:** 02 May 2017

Citation: Vinoth Kumar, Thamilselvam P. Fracture Penis: A Case Report. Int J Nur Care. 2017; 1-3.

ABSTRACT

Penile fracture remains a rare and a serious urosurgical entity. It is seen as discontinuity; its site, nature and extent of penile urethra can be accurately depicted even by routine ultrasound and retrograde urethrogram. It is rupture of one or both of the tunica albuginea, the fibrous coverings that envelop the penis's corpora cavernosa and urethra. Traumatic injuries of the penis often occur in the erected state. Due to the possible embarrassment, this condition has been underreported. Typically, the patient reports a snap or cracking sound accompanied by sharp pain and rapid penile detumescence, followed by immediate development of swelling and angulation. The common causes include direct injuries, forceful masturbation, or vigorous sexual intercourse. Most injuries to the penis need immediate surgical treatment [1]. Diagnosis is usually clinical, and urethral injury should be suspected in the penile fracture, especially in those cases with bilateral cavernosal rupture [2]. This case report would help all readers aware about the existence of this entity so that not only a timely medical attention is sought for that it also is adequately provided in order to prevent physical as well as psychological problems [3].

Keywords

Fracture, Urethra, Penis, Swelling.

Penile fracture remains a rare, yet likely under reported condition. The first documented report of this injury was more than 1000 years ago [4]. More than 1600 cases of penile fracture have appeared in the medical literature to date [5]. Fracture of the penis is a tear in the tunica albuginea of the corpora cavernosa which may be associated with injury to the corpus spongiosum and urethra [4]. Diagnosis is usually clinical, and urethral injury should be suspected in the penile fracture, especially in those cases with bilateral cavernosal rupture [6]. The usual cause is abrupt bending of the erect penis by blunt trauma most commonly during sexual intercourse. A crackling sound, pain, detumescence, bruising, swelling, and bleeding per urethra are the common symptoms reported by the patients. Early surgical management is the treatment of choice with a low incidence of complications [7].

We report a case, 37 year old gentleman presented to casualty with history of pain and swelling of the penis. He gave history

of coital injury and as the erect penis slipped out of vagina and hit against partner's perineum resulting in buckling injury. There was a classical click sound followed by pain, swelling and loss of erection. Post incident patient was not able to pass urine.

On physical examination there was swelling of penis with deviation of phallus to one side (Figure 1). Blood was noted in the external urethral meatus (Figure 2) and bladder was distended.

Patient was diagnosed as penile fracture by clinical examination Retrograde Urethrogram was done and it showed the rupture in urethra –extravasation of contrast (Figure 3).

The patient underwent immediate surgical exploration and repair of the fracture (Figure 4).

Circumferential sub coronal degloving incision was made and the hematoma was evacuated. The urethral injury was repaired. The tunica albuginea and corpus cavernosum were sutured. Skin was sutured (Figure 5).

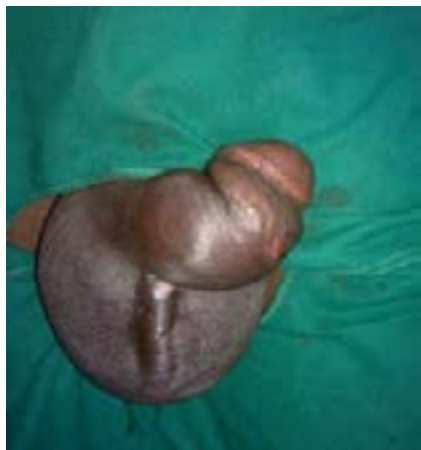

Figure 1: Swelling of the penis with deviation to left.

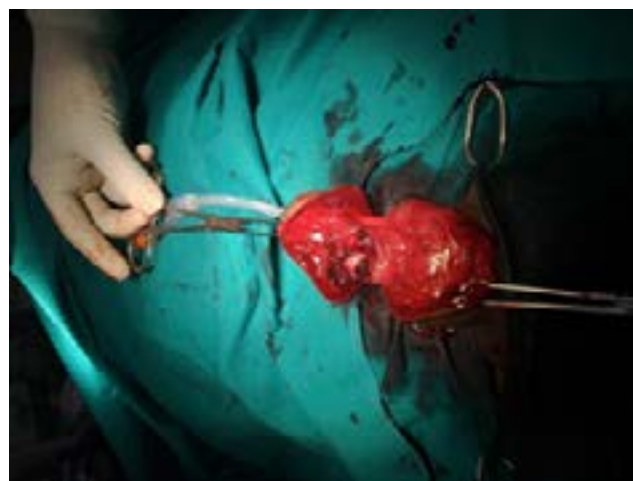

Figure 4: Surgical exploration showing urethral injury and the injury of tunica albuginea and corpus cavernosum.

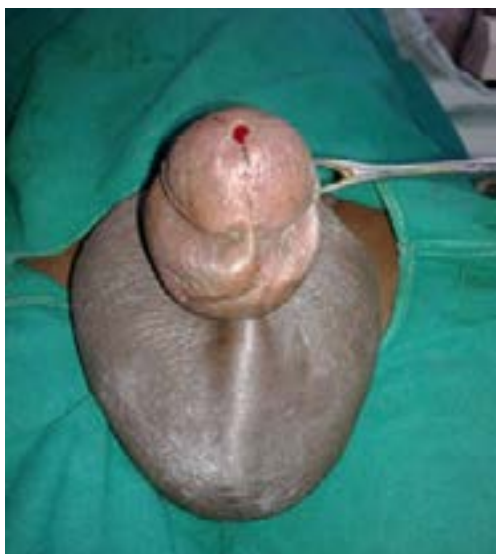

Figure 2: The blood was noted in the external urethral meatus.

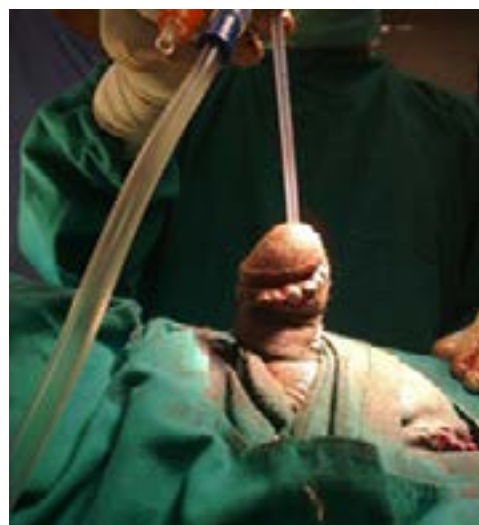


Figure 5: After suturing the injured tissues.

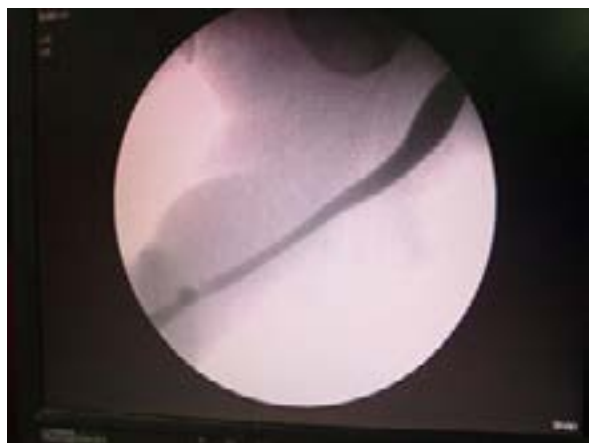


Figure 3: Retrograde Urethrogram shows rupture in urethra – extravasation of contrast.

The post operative period went very well without any complications. Postoperatively patient was prescribed antibiotics and a prophylactic urethral catheter was kept for 10 days, which was subsequently removed. He was instructed to abstain from intercourse for 4 months. After six months we demonstrated satisfactory erectile function by penile Doppler.

Discussion

Fracture penis in general surgical practice is rare to be reported. It is always embarrassing for patients as well as partners hence often go unreported. Complications may be early or late. In early complications bleeding, pain, penile oedema, painful erections and wound sepsis are noted. Late complications include erectile dysfunction, chordee, fibrous plaque, there may be palpable knots of non-absorbable suture material used to repair the tunica defect, stricture urethra or urethra cutaneous fistula in cases of urethral tear [8]. Erectile dysfunction is usually self-limiting and resolves in 3-4 months, fibrous plaque is treated by its excision [9].

Normally inside the penile shaft, erectile tissues is arranged in columnar fashion [10-13]. Dorsolaterally there are two corpora cavernosa and the ventromedially there is a corpus spongiosum, each enclosed in tunica albuginea. Ventral extension of the Buck's fascia encloses the single corpus spongiosum whereas the dorsal one encloses the two corpora cavernosa [10,11].

With sudden rise in the intra cavernosal pressure due to any extrinsic force the already thinned tunica albuginea of the erect penis gives away. Although, vaginal intercourse still remains the single commonest cause [10]; any activity carried in an erect state of penis like masturbation, self-manipulation, sexual intercourse, rolling over in bed; can cause direct penile trauma and result in fractures. Increased use of pharmaceutical agents that enhance the duration of erection further enhances the chances of penile fractures. Preexisting urethral or periurethral infections [11] and injuries in this region increase the chances of penile fractures [3].

References

1. Wen J, Li HZ, Ji ZG, et al. Fracture penis: a case more heard about than seen in general surgical practice. *BMJ Case Rep* 2013.
2. Dwivedi S, Chowdhary K, Mittal A, et al. Fracture penis: An interesting case report. *International Journal of Clinical and Experimental Physiology*. 2015; 2: 139-141.
3. Kachewar SG. Fractured Penis- A case report. *International J of Healthcare & Biomedical Research*. 2013; 1: 321-324.
4. Eke N. Fracture of the penis. *Br J Surg*. 2001; 82: 555-565.
5. Zargooshi J. Penile fracture in Kermanshah, Iran: Report of 172 cases. *J Urol*. 2000; 164: 364-366.
6. Dever DP, Saraf PG, Catanese RP, et al. Penile fracture: Operative management and cavernosography. *Urology*. 1983; 22:394-396.
7. Jack GS, Garraway I, Reznichuk R, et al. Current treatment options for penile fractures. *Rev Urol*. 2004; 6: 114-120.
8. Eke N. Fracture of Penis. *Br J Surg*. 2002; 89: 555-565.
9. Sahoo MR, Nayak AK, Nayak TK, et al. Case report-Fracture penis: a case more heard about than seen in general surgical practice. *BMJ*. 2013; 12: 10.
10. Ruckle HC, Hadley HR, Lui PD. Fracture of penis: diagnosis and management. *Urology* 1992; 40:33-35.
11. Brotzman GL. Penile fracture. *J Am Board Fam Pract*. 1991; 4: 351-353.
12. Bannister LH, Dyson M. Reproductive system. In: Williams PL, eds. *Gray's anatomy*. 38th ed. New York, NY: Churchill Livingstone. 1995; 1847-1880.
13. Rosse C, Gaddum-Rosse P. Pelvis and perineum. In: Rosse C, Gaddum-Rosse P, eds. *Hollinhead's textbook of anatomy*. 5th ed. Philadelphia, Pa: Lippincott-Raven. 1997; 639-700.