

## Giant Acrochordon Arising from Scrotum: An Uncommon Presentation

Evi Mustikawati Arifin<sup>1\*</sup>, Astrid Laurentia Harianto<sup>2</sup> and Suswardana<sup>3</sup>

<sup>1</sup>Department of Dermatology, Parikesit MA General Hospital, Kutai Kartanegara, Kalimantan, Indonesia.

<sup>2</sup>Department of Dermatology, Santa Anna Hospital, Kendari, South East Sulawesi, Indonesia.

<sup>3</sup>Department of Dermatology, Navy Seal Hospital dr. Mintohardjo, Jakarta, Indonesia.

### \*Correspondence:

Evi Mustikawati Arifin, Department of Dermatology, Parikesit MA General Hospital, Kutai Kartanegara, Kalimantan, Indonesia, E-mail: epong\_bs@yahoo.com.

**Received:** 21 February 2018; **Accepted:** 16 March 2018

**Citation:** Evi Mustikawati Arifin, Astrid Laurentia Harianto, Suswardana. Giant Acrochordon Arising from Scrotum: An Uncommon Presentation. Med - Clin Res & Rev. 2018; 2(2): 1-3.

### ABSTRACT

**Background:** Acrochordons have an irregular or smooth surface and most commonly located on eye lids, neck, axillae, trunk, groin, and on the lumbar area. There are a few case reports of giant acrochordons including one reported on male external genitalia.

**Case Report:** A 50-year-old man with a pedunculated mass, diameter 9 cm, arising from right scrotum since 3 years ago. Body mass index was 27.3 kg/m<sup>2</sup>. There was no pain, redness and no ulceration. The lesion was totally removed with CO<sub>2</sub> laser under local anesthesia. Diagosis was confirmed by histopathological examination.

**Discussion:** The predisposing factor in this patient is obesity. Acrochordon can be removed with electrodesiccation, curved or serrated blade scissors, cryotherapy or even laser surgery. CO<sub>2</sub> laser surgery under local anesthesia in this patient was cosmetically acceptable by simple procedure.

**Summary:** According to our search using PubMed Journal. This case so far is the largest acrochordon arising from scrotum and successfully treated using CO<sub>2</sub> laser.

### Keywords

Acrochordon, Giant, Scrotum, Laser.

### Introduction

An acrochordon, also known as a (cutaneous) skin tag, or fibroepithelial polyp (FEP), is a small, soft, common, benign, usually pedunculated neoplasm that is found particularly in persons who are obese. It is usually skin colored or hyperpigmented, and it may appear as a surface nodule or papilloma on healthy skin. Most acrochordons vary in size from 2-5 mm in diameter, although larger acrochordons up to 5 cm in diameter are sometimes evident [1,2]. They are usually diagnosed by clinical features. However, histological examination may be needed for diagnosis in unusual cases [2-4]. There are many methods available for removal of skin tags. Cryosurgery or freezing, blade scissor, surgical excision, electrodesiccation Some individuals also choose to have the skin tag cut off with laser surgery [1,4-6].

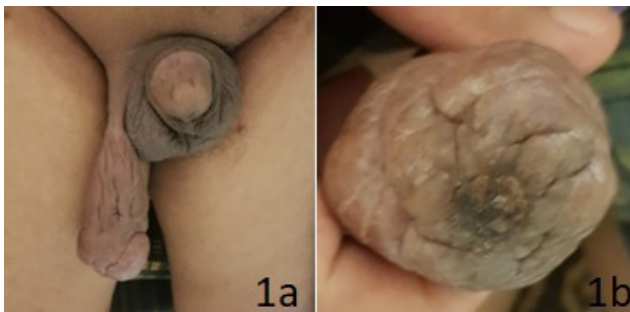
### Case Report

A 50-year-old man presented in the outpatient department with a mass hanging from skin scrotal since 3 years. Mass was small in size to begin with no complaints but gradually increased. Patient experienced discomfort while walking due to the weight and rubbing of the mass between his thighs and became apprehensive of its growing size. There was no pain, pruritus, fever, redness, ulceration, bleeding and discharge, the size increase repeatedly, aggravating/relieving factors or diurnal change in size.

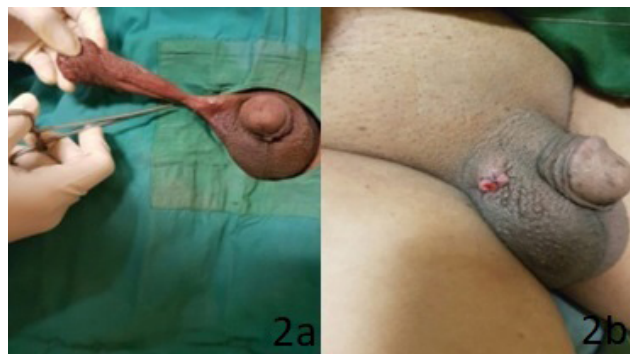Patient was overweight (body mass index 27.3 kg/m<sup>2</sup>). Dermatological examination revealed a single, skin-coloured, pedunculated, pear-shaped, non-tender, soft fleshy mass with wrinkled surface measuring 9 × 5 x 2,5 cm and arising from a thin stalk from posterior part of right scrotum (Figures 1a and 1b) and distorting its shape. There was no redness, discharge or ulceration. The mass was nonpulsatile, nonreducible, with no

impulse on coughing, any palpable thrill or bruit with any regional lymphadenopathy. Systemic and genitourinary examination was normal. Blood sugar and lipid profile were normal. The mass was diagnosed as acrochordon due to its pedunculated attachment, soft consistency and free mobility.

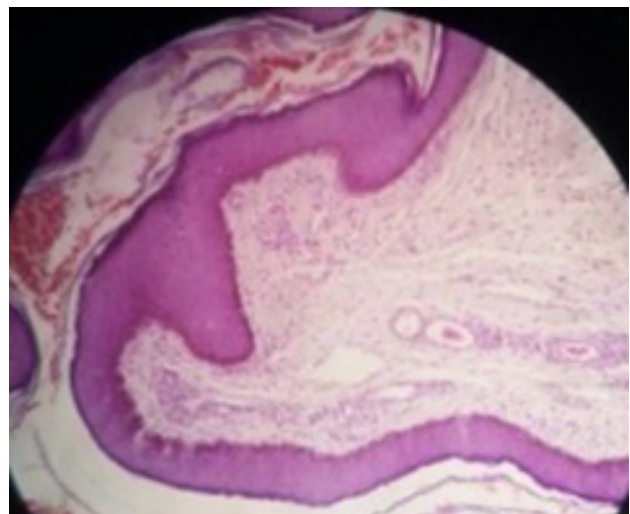
The lesion was totally removed with CO<sub>2</sub> laser under local anesthesia (Figures 2a and 2b). Histopathological examination revealed mature stratified squamous epithelium, increased fibrocollagenous tissue in the stroma, thickened blood vessels, stellate fibroblast and sparse perivascular chronic mononuclear inflammatory infiltrate with no evidence of malignancy (Figure 3). The diagnosis of acrochordon was confirmed. Written informed consent was obtained from the patient for publication of this case report.



**Figures 1a and 1b:** Giant acrochordon of the right scrotum.



**Figures 2a and 2b:** a) Giant acrochordon preoperative. b) Immediate post-operative.



**Figure 3:** Hyperplastic epidermis showing mature stratified squamous epithelium, increased fibrocollagenous tissue in the stroma, thickened blood vessels, stellate fibroblast and sparse perivascular chronic mononuclear inflammatory infiltrate with no evidence of malignancy. (H and E, 100×).

### Discussion

Acrochordons have been reported to have an incidence of 46% in the general population [1,2,4,5]. An equal prevalence of acrochordons exists in males and females. When present, acrochordons increase in frequency up through the fifth decade. As many as 59% of persons may have acrochordons by the time they are aged 70 years [1,5].

The majority of acrochordons are asymptomatic and do not cause pain unless they become inflamed or irritated, but may create discomfort when in contact with clothing or jewelry [1,6]. In our case, there was uncomfortable with the appearance of this lesion and discomfort while walking due to the weight and rubbing of the mass between his thighs. Acrochordons vary in size, typically from 1 to 5 mm in diameter, though diameters > 5 mm have been reported [1-5].

Acrochordons have an irregular or smooth surface and most commonly located on eye lids, neck, axillae, trunk, groin, and on the lumbar area [1-5] Giant acrochordons are usually observed on the lower half of the body, particularly in the penile or vulvovaginal region. There are a few case reports of giant achrochordons including one reported on male external genitalia [2,3]. There are several report of giant acrochordons on the labium majus [7,8] thigh [9] and also axilla [10].The incidence of these lesions on the male genitalia only one case similar to the present case have been published in literature is An Unusual Mass on the Skin of Scrotum: Acrochordon by Zancactutar et al. [3] in our case is the largest one.

Although the etiopathogenesis of acrochordons has not been definitively described, it has been attributed to metabolic disorders; insulin resistance, diabetes mellitus, dyslipidemia, and obesity [11]. Frequent irritation of skin creases in obese patients and dermal wear due to aging have also been implicated as important etiologies [1-3].In our case, obesity as predisposing factor.

Acrochordons are generally treated for cosmetic reasons. The reason is that genital skin tags are felt during sex and it is not uncommon for both the person and his/her sex partner to suspect them of some contagious disease, especially of sexually-transmitted diseases (STDs). Another reason for concern over genital skin tags is their risk of hosting infections. But on the whole, groin skin tags themselves are not infectious or malignant. They are just skin tags of the genitalia in men and women of various age groups [1]. Small, pedunculated acrochordons may be removed with curved or serrated blade scissors, cryotherapy or even laser surgery. Electrodesiccation is another option. Larger skin tags require excision followed by repair and cosmetic enhancemen [2,3,6]. Many patients are afraid of hospitalization and surgery because of fear of bleeding and possible complications. In the case was completely

removed with CO<sub>2</sub> laser surgery under local anesthesia was quite acceptable to the patient and very good cosmetically acceptable result by simple outpatient procedure.

## References

1. Rajput DA, Gedam JK, Patel A, et al. Unusual Presentation of Acrochordon. *Indian J of Clin Prac.* 2013; 24: 436-438.
2. Kumar YHK, Sujatha C, Ambika H, et al. Penile acrochordon: An unusual site of presentation– A case report and review of the literature. *Int J of Health & Allied Sci.* 2012; 1: 122-125.
3. Sancaktutar AA, Bozkurt Y, Tepeler A, et al. Unusual Mass on the Skin of Scrotum: Acrochordon. *J Clin Anal Med.* 2015; 6: 112-113.
4. Zebitay AG, Kahramanoglu I, Ilhan O, et al. Unusually Large Skin Tag of Labium Majus. *Open J of Obs and Gyn.* 2014; 4: 699-702.
5. Agarwal A, Garg C, Mukherjee S, et al. Giant acrochordon of vulva: A rare occurrence. *NJDVL.* 2015; 13: 70-72.
6. Choudhary ST. Treatment of Unusually Large Acrochordon by Shave Excision and Electrodesiccation. *J Cutan Aesthet Surg.* 2008; 1: 21-22.
7. Ozkol HU, Bulut G, Gumus S, et al. Ulcerated giant labial acrochordon in a child. *Indian Dermatol Online J.* 2015; 6: 60-61.
8. Garg S, Baveja. Giant Acrochordon of Labium Majora: An Uncommon Manifestation of a Common Disease. *J Cutan Aesthet Surg.* 2015; 8: 119-120.
9. Bahce ZS, Akbulut S, Sogutcu N, et al. Giant Acrochordon Arising from the Tigh. *J Coll Physicians Surg Park.* 2015; 25: 839-840.
10. Alkhalili E, Prapasiri S, Russle J. Giant acrochordon of the axilla. *BMJ Case Rep* 2015.
11. Salem SA, Attia EA, Osman WM, et al. Skin tags: a link between lesional mast cell count/tryptase expression and obesity and dyslipidemia. *Indian J Dermatol.* 2013; 58: 240.