

Immediate Direct Rehabilitation of Fractured Maxillary Central Incisors

Abhinav Singhal¹ and Aditi Jain^{2*}

¹Sr Lecturer, MDS, Department of Pedodontics & Preventive Dentistry, Maitri College of Dentistry & Research Center, Anjora, India.

²Sr. lecturer, MDS, Department of Conservative Dentistry & Endodontics, Maitri College of Dentistry & Research Center, Anjora India.

*Correspondence:

Aditi Jain, Sr. lecturer, MDS, Department of Conservative Dentistry & Endodontics, Maitri College of Dentistry & Research Center, Anjora India, E-mail: aditijain300789@gmail.com.

Received: 21 December 2017; Accepted: 08 January 2018

Citation: Abhinav singhal, Aditi jain. Immediate Direct Rehabilitation of Fractured Maxillary Central Incisors. Int J Oral Health Dent Manag. 2018; 2(1); 1-3.

ABSTRACT

The coronal fracture is an unexpected occurrence and requires professional preparation for the urgent approach. A coronal fracture involving non-complicated enamel and dentin might receive different kinds of treatment such as re-attachment of fragments or restoration with composite materials. The reattachment of crown fragment is a conservative approach one should always consider for young patients. A trauma to anterior teeth is an agonizing experience and creates an emotional impact on both the patient and parents. Recent developments in adhesive technology in combination with advancements in restorative materials have resulted in use of natural tooth fragment for management of fractured anterior teeth. This paper reports a case of a permanent both maxillary central incisor with fracture treated using composite resin restoration and post and core along with ceramic capping.

Keywords

Crown fracture, Dental trauma, Permanent teeth.

Introduction

The traumatic injuries in children and adolescents are a common problem, and some reports have been observed that its prevalence has increased in recent decades [1-4]. In permanent dentition, the coronal fractures are a common occurrence, particularly in children between 8 and 11 years old [2,3]. Coronal fractures represent a high proportion of the dental trauma in the permanent dentition ranging between 26-76% of dental injury, and approximately 16% of coronal fractures are complicated presenting pulp exposure [3].

Aesthetic and functional rehabilitation is the primary goal of the treatment of crown-fractured tooth. Actually, an alternative approach, which is becoming more attractive due to the technology of new dentin bonding agents, is fragment bonding [3,4]; however, in cases of absence of the fragment, it becomes essential to preserve the remnant tooth structure with a composite resin restoration [5-8]. The introduction of composite in combination with the use of acid etch technique to bond composite to enamel, made restoration possible for the fractured incisor, with little or no additional tooth preparation.

Case Report

A 22 year male reported to the department of conservative dentistry & endodontics, Maitri college of dentistry & research center, with the chief complaint of pain and mobility in upper front region since 2 hours. History revealed trauma resulting from a skateboarding accident that occurred 2 hours earlier. There was soft tissue injury on extra oral examination and intra oral examination revealed crown fracture of both the maxillary central incisors (Figure 1).

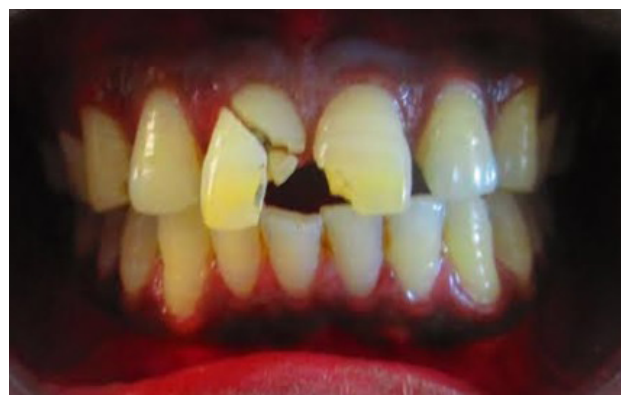

Figure 1: Preoperative photograph showing complicated crown fracture of right maxillary central incisor in the cervical third and Ellis class II

fracture with left central incisor.

A detailed explanation about the treatment plan was given to the patient, which included endodontic treatment, then post. The treatment plan was accepted by the patient and consent was taken. Local anesthetic was administered and the fracture segment was removed. Pulp tissue was extirpated and cleaning and shaping was done. The root canal was enlarged to ISO size 40 at working length. During biomechanical preparation, the canal was irrigated with sodium hypochlorite. The root canal was dried with paper points and obturation was completed in a single visit (Figure 2). The root canal was then prepared with peeso reamer to receive a post. The prefabricated metal post was tried in the canal, adjusted and then placed followed by PFM Capping (Figure 3). Maxillary left central incisor was then restored using composite resin restoration. The tooth was polished with the polishing disc. Occlusion was checked and post operative instructions were given (Figure 4). Clinical and radiographic examinations were carried out after 1 month, 3 months, 6 months and the tooth responded favorably (Figure 5).

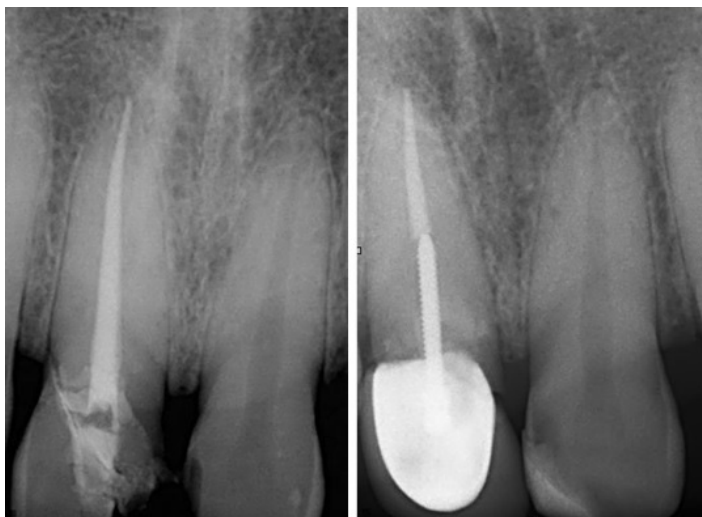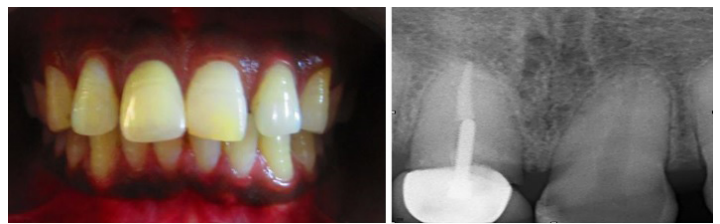


Figure 2: Complete obturation was done with right maxillary central incisor.

Figure 3: Apical 4 mm of gutta percha followed by post along with the PFM capping.

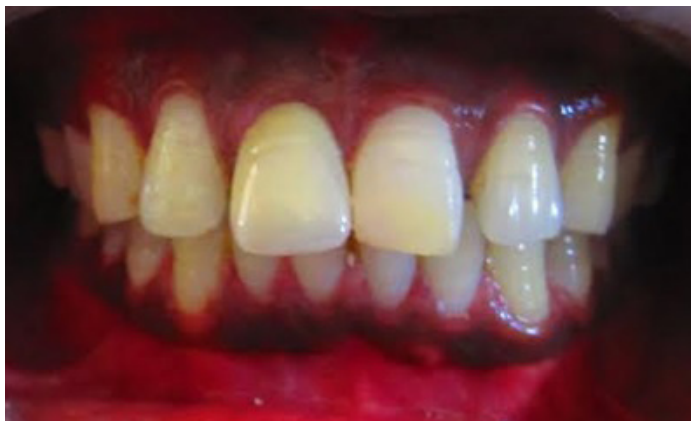

Figure 4: Postoperative photograph showing PFM capping with right central and composite restoration with left maxillary central incisor.



Figures 5 and 6: Months follow-up clinically and radiographically.

Discussion

The preservation of the fragment is not always possible, because the circumstances in which the fractures occur, sometimes does not allow the patient to find it, which guides the treatment for a reconstruction with composite resin. Composite resin restoration for the restoration of permanent incisors that have minimum or not very extensive crown fractures is an excellent approach due to a conservative, timely, & economical treatment option [5-9].

The choice of resin composite should be focused on aspects related to the strength and aesthetics. Within this context, the composite layering is the key to obtaining esthetically successful restorations. According Nahsan et al. [8] young teeth show a naturally high value and thus require resins with such characteristics; in consequence, the reproduction of enamel should be done with composite resins that present transparent characteristics.

Resin stratification initiating from the palatal enamel is the best choice, particularly in fractured anterior teeth, with a transparent composite to create the underlying structure for the subsequent layers [7]. The palatal enamel can be constructed with the use of a polyester matrix, pre-fabricated acetate crowns, or personalized guides like silicone matrix [8]. The silicone matrix option has advantages in restorative procedures by providing reduction of the operating time [7], maintenance of the cervico-incisal and mesiodistal dimensions besides appropriate control of the thickness of the resin increment, and enough support for the build-up of material from the palatal aspect.

The variation of some characteristics of the composite materials like translucency and opacity of composite resins requires the professional to know the different esthetic restorative materials and their optical behavior and may thus replace or correct color tones during the restorative procedure [7-11].

Several variables can affect the longevity of this type of restoration including the extent of the crown fracture, the restoration size, the occlusion of the restored tooth, and the overall prognosis of the injured tooth. The choice of resin should be focused on aspects related to the strength and aesthetics. The present hybrid resins, due to its high percentage of inorganic filler and diversity of colors for enamel and dentine, allow satisfactory clinical results, in terms of longevity of the restoration.

In the present case, the location and aspect of the fracture combined with a balanced occlusion may have favored the clinical success. Limitations of the adhesives restoration techniques can

be attributed to detachment of the restoration by a new trauma or the restoration does not recover its original color. With regard to the restorative procedure, the applied technique has facilitated the obtaining of dental contours and convexities, which would be more labored and lengthy in a direct restorative technique. If handled properly, prognosis of the tooth, after traumatic crown fracture, is satisfactory.

Conclusion

The composite resin restoration of permanent incisors with crown fractures is a simple procedure that should be planned and executed with attention to dental contours and convexities, facilitating the re-establishment of function and aesthetics. Use of post allow not only creation of esthetic restorations but also facilitates the preservation and reinforcement of tooth structure.

References

1. Andreasen JO, Andreasen FM, Andersson L. Textbook and color atlas of traumatic injuries to the teeth. 4th edn. Copenhagen, Denmark: Blackwell Munksgaard. 2007.
2. Terry DA. Direct reconstruction of the maxillary anterior dentition with composite resin: a case report. *Pract Periodontics Aesthet Dent.* 1999; 11: 361-367.
3. Oliveira GM, Ritter AV. Composite resin restorations of permanent incisors with crown fractures. *Pediatr Dent.* 2009; 31: 102-109.
4. Ozel E, Kazandag MK, Soyman M, et al. Two-year follow-up of fractured anterior teeth restored with direct composite resin: Report of three cases. *Dent Traumatol.* 2008; 24: 589-592.
5. Behle C. Placement of direct composite veneers utilizing a silicone buildup guide and intraoral mock-up. *Pract Periodontics Aesthet Dent.* 2000; 12: 259-266.
6. Saghezchi KS. Treatment of a broken central incisor in children after trauma. *J Cosmet Dent.* 2003; 19: 108-112.
7. Sakai VT, Anzai A, Silva SMB, et al. Predictable esthetic treatment of fractured anterior teeth: A clinical report. *Dent Traumatol.* 2007; 23: 371-375.
8. Farik B, Munksgaard EC, Andreasen JO, et al. Fractured teeth bonded with dentin adhesives with and without unfilled resin. *Dent Traumatol.* 2002; 18: 66-669.
9. Nahsan FP, Mondelli RF, Franco EB, et al. Clinical strategies for esthetic excellence in anterior tooth restorations: Understanding color and composite resin selection. *J Appl Oral Sci.* 2012; 20: 151-156.
10. Rappeli G, Massaccesi C, Putignano A. Clinical procedures for the immediate reattachment of a tooth fragment. *Dent Traumatol.* 2002; 18: 281-284.