

Small Stone Syndrome: A Reason to Broaden Your Differential for Chronic Low Back Pain

Matthew Villerot D.O, Larry Manders M.D., M.B.A*, and Branden Yaldou M.D.

Anesthesiology, Beaumont Health, Royal Oak, Michigan/United States of America.

*Correspondence:

Larry Manders, M.D., M.B.A., Department: Anesthesiology, Beaumont Health, Royal Oak, Michigan/United States of America, Tel: 313-433-3486; Fax: 248-898-7459; E-mail: Lmandersjr@gmail.com or Larry.Manders@Beaumont.edu.

Received: 14 December 2017; Accepted: 08 January 2018

Citation: Villerot M, Manders L, Yaldou B. Small Stone Syndrome: A Reason to Broaden Your Differential for Chronic Low Back Pain. J Clin Anesth Res. 2018; 2(1): 1-2.

ABSTRACT

Developing a broad differential for chronic back pain is important in terms of work-up, and eventual treatment. We present a case of a sixty-nine-year old male with chronic back pain, failing multiple treatments and medications, which were eventually diagnosed with non-obstructing renal calculi. We believe it is imperative that pain management physicians are cognizant of small stone syndrome, and that they widen their differential to include rarer causes of back pain when treatment modalities prove ineffective. As demonstrated by our case, ineffective treatment, unneeded procedures, and poor patient satisfaction, may result when a broad differential is not utilized.

Keywords

Small stone syndrome, Chronic lower back pain, Renal calculi.

Introduction

Chronic back pain is the second most common cause of disability in the United States [1]. It is estimated that more than 80% of individuals will have an episode during their lifetime [2]. Numerous pathologies exist, such as muscle strain, disc disease, arthritis, and skeletal abnormalities. Treatment for chronic back pain is challenging, as determining the source and finding an efficacious analgesic modality is often difficult. This case demonstrates a lesser-known cause of chronic back pain; small stone syndrome. It also stresses the importance of broadening a differential diagnosis when back pain is resistant to current treatment modalities, allowing the provider to deliver more effective care to a patient.

Case Description

A 69-year-old male presented for follow up visit for chronic back pain. His back pain was primarily left lower back, 6/10 on average, with 10/10 episodic flairs. The pain was dull, achy, and constant. Patient's back pain began 8 years prior. It had failed multiple interventions, including lumbar/caudal epidural steroid injections, lumbar medial branch nerve blocks, radiofrequency ablation, posterior left L4-5 laminectomy, and fusion. Patient stated pain

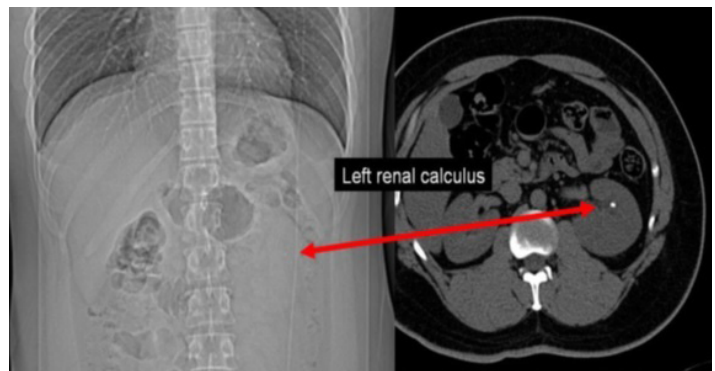
was never greatly improved, regardless of treatment. He was medically managed with extended release morphine 15 mg Q8H and short acting morphine 15 mg TID PRN. Three months prior to this current visit, the patient independently performed a literature search and came across small stone syndrome. He stated he had kidney stones decades early and believed this pain was similar in characteristics. After referral to a urologist, he presented his case and the physician performed a ureteroscopy. Three left lower renal calculi, measuring < 4mm, were discovered and removed. Upon removal patient had immediate relief of pain. Patient was completely weaned from opioids with continued resolution of pain.

Discussion

Until recently, non-obstructing renal stones were not highly considered as foci for renal colic or chronic pain. In a few studies, back in the 1980's, there was a brief discussion over the justification of small renal calculi, and if that proved to be effective in renal colic [5-7]. Since then, the general consensus has been to leave small (<5mm), non-obstructive, stones alone, as they have not been thought to be the cause of the pain. However, a more recent study, Jura et al, demonstrated that in chronic flank pain patients, with non-obstructing calyceal stones (<4mm in diameter), and no other foci of pain, removal of the stone provided significant pain relief. 85% of patients had complete pain relief,

whereas the remaining 15% had partial resolution of pain. Thus, they coined the term small stone syndrome. The study's findings have been supported by similar results in acute pain patients with non-obstructing renal stones.

In a 2008 study, looking at the etiology of patients presenting to ED with renal colic, they found that 18% of them had non-obstructing stones on the side of pain, with no other explanation. All were discharged, and claimed pain was due to unknown abdominal etiology. Fourteen of these patients presented to ED on multiple occasions, always with the same discharge diagnosis [4]. We believe it is imperative that pain management physicians are cognizant of this syndrome, and that they widen their differential to include more rare causes of back pain when current treatment modalities prove ineffective. The thorough list of differential diagnoses, including small stone syndrome, is provided in table 1. As demonstrated by our case, ineffective treatment, possibly unneeded procedures, and poor patient satisfaction may result when a broad differential is not utilized.



References

1. [No authors listed]. From the Centers of Disease Control and Prevention. Prevalence of disabilities and associated health conditions among adults-United States. *JAMA*. 2001; 285: 1571-1572.
2. Rudin Di. Epidemiology and risk factors for spine pain. *Neurol Clin*. 2007; 25: 353-371.
3. Jura YH, Lahey S, Eisner BH, et al. Ureteroscopic treatment of patients with small, painful, non-obstructing renal stones: the small stone syndrome. *Clin Nephrol*. 2013; 79: 45-49.
4. Furlan A, Federle MP, Yealy DM, et al. Nonobstructing renal stones on unenhanced CT: a real cause for renal colic?. *AJR Am J Roentgenol*. 2008; 190: W125-W127.
5. Mee SL, Thuroff JW. Small caliceal stones: is extracorporeal shock wave lithotripsy justified? *J Urol*. 1988; 139: 908-910.
6. Coury TA, Sonda LP, Lingeman JE, et al. Treatment of painful caliceal stones. *Urology*. 1988; 32: 119-123.
7. Andersson L, Sylven M. Small renal caliceal calculi as a cause of pain. *J Urol*. 1983; 130: 752-753.

Mechanical Causes	Nonmechanical Causes	Causes of Referred Pain
Idiopathic (sprain, strain)	Malignancy	Pelvic disease (prostatitis, endometriosis, pelvic inflammatory disease)
Spondylosis (disk, annulus, facet)	Infection	Renal disease (kidney stones, pyelonephritis, perinephric abscess, small stone syndrome)
Compression fracture	Inflammatory spondyloarthropathy	Aortic aneurysm
Traumatic fracture	Osteochondrosis	Gastrointestinal disease
Alignment disorders	Paget's disease of bone	

Table 1: Differential Diagnosis of Low Back Pain.